

Expert Advice Forum of AO Spine International

**“Incidental lumbar durotomy: one problem to be solved by spine surgeons from five continents”**

Asdrubal Falavigna (Brazil) 1  
André Castilho (Brazil) 2  
Yoshiharo Kawaguchi (Japan) 3  
Bastian Storzer (München) 4  
Karsten Wiechert (München) 4  
Nestor Taboada (Colombia) 5  
Jason Ilias Liounakos (USA) 6  
Michael Yung-Shun Wang (USA) 6  
Avelino Parajón (Madrid) 7  
S. Rajasekaran (India) 8

1. Neurosurgical Department, Caxias do Sul University, Caxias do Sul, Brazil.
2. Orthopaedic Department, Hospital Mater Dei, Belo Horizonte, Brazil.
3. Department of Orthopaedic Surgery, University of Toyama, Toyama, Japan.
4. Neurosurgical Department, Schoen Clinic München Harlaching German, Säbener Strasse 112, 81547 München.
5. Neurosurgical Department, Barranchilla, Colombia.
6. Neurosurgical Department, University of Miami Miller School of Medicine, Miami, USA.
7. Neurosurgical Department, University Hospital of Ramón y Cajal. Colmenar, Madrid.
8. Department of Orthopaedics and Spine Surgery, Ganga Hospital, Coimbatore, Tamil Nadu, India.

## **Introduction**

Incidental durotomy (ID), resulting in cerebral spinal fluid (CSF) leakage, is one of the most common and often challenging complications in spine surgery.<sup>1</sup> The incidence varies widely, ranging from 1% to 17%, depending on the location in the spine and type of procedure.<sup>1,2</sup> Revision surgeries present almost twice the risk of CSF leakage as primary surgery. Meticulous decompression and regular use of a microscope probably reduce ID in the cervical spine when compared with the lumbar spine.<sup>3,4</sup> Some types of lumbar pathologies have a higher chance of ID, such as spondylolisthesis, spinal stenosis, and, in particular, synovial cyst.<sup>3,5,6</sup> ID can be twice as frequent in open lumbar surgery, especially in revision cases, compared to minimally invasive surgery (MIS).<sup>4</sup> The prevalence of ID in surgery involving anterior or lateral access is around 2% and can be as high as 37% in full endoscopic treatment of synovial cysts.<sup>6,7,8</sup>

The consequences of a non-identified durotomy can be devastating<sup>9</sup>, with complications including infection, pseudo meningocele,<sup>10</sup> meningitis,<sup>11</sup> radiculopathy, caudal displacement of

intracranial content, and subdural hematoma. A retrospective analysis of hospital costs for elderly patients who underwent discectomy with ID complication showed an increase of over \$4000.<sup>12</sup>

A gold standard for management of intraoperative and postoperative cerebrospinal fluid leakage is still lacking in the literature.<sup>13, 14</sup> A survey of German, Austrian, and Swiss spine surgeons showed that isolated bed rest, simple suture, use of fibrin sealant patch and fibrin glue were all treatment strategies.<sup>13</sup> In that study, most surgeons prescribed 24 to 48hrs post-operative bed rest.<sup>13</sup> Another survey conducted in Germany showed no consensus regarding the treatment of incidental durotomy.<sup>14</sup> Considering the different approaches to the lumbar spine, ID management should be individualized. The objective of this paper is to describe the stepwise treatment of intraoperative ID by expert spine surgeons from five continents for four clinical scenarios. The experts were Yoshiharu Kawaguchi (YK), Bastian Storzer and Karsten Wiechert (BS & KW), Nestor Taboada (NT), Jason Ilias Liounakos and Michael Yung-Shun Wang (JL & MW), Avelino Parajón (AP), and S. Rajasekaran (SR).

The first scenario involves a CSF leak during discectomy through the lateral or anterior approach to the lumbar spine. In the second scenario the ID was observed during a minimally invasive transforaminal lumbar interbody fusion (MIS-TLIF) approach. In the third scenario the CSF leak occurred as a result of a pure endoscopy technique. The fourth scenario was postoperative CSF leakage after lumbar fusion through a lateral approach for cage placement and a paravertebral posterior approach for nerve decompression and percutaneous pedicle screw.

The questions asked concern surgical tips and tricks to handle the ID, the placement of biological fibrin glue, synthetic sealant, tissue grafting, and postoperative maintenance such as bed rest, lumbar drainage, and prophylactic antibiotics. The experts commented on how they would prevent or avoid ID. The postoperative scenario was related to the diagnosis of late dural tear, repair through suture, biologic glues, lumbar CSF drainage, and postoperative maintenance. The decision-making process of each surgeon was collected and analyzed.

**Scenario 1:** The surgeon observed a CSF leak while the intervertebral disc was removed through the lateral or anterior approach to the lumbar spine.

#### **Comments from experts**

YK:

It is very difficult to detect or even more repair the dural tear from the lateral or anterior approach. I would use fibrin glue and a polyglycol acid sheet in a small dural tear. If there is a high-flow CSF fistula, I would probably recommend lumbar CSF drainage by posterior approach. Bed rest for several days is one of the best ways to manage a CSF leak. Bed rest for one week could be necessary when CSF lumbar drainage is indicated. Prophylactic antibiotics are not usually used. To avoid a dural tear during lateral or anterior decompression it is necessary to clearly define the interface between the intervertebral disc and the dura mater. It is necessary to avoid deep excision from the anterior surface of the intervertebral disc and/or a posterior placement of the cage through lateral approach. Appropriate instruments with depth marks are useful to know the depth of the insertion into the intervertebral disc.

#### BS & KW:

The proposed treatment for these cases is to avoid further CSF loss by placing viscose pads while proceeding with further decompression until the borders of the dura defect are exposed. Repone fibers if needed and when possible, stitch the leak with Prolene 6/0. Suture is rarely possible from an anterior approach. Alternatively, a sandwich technique with a collagen fleece with human fibrinogen and thrombin on one side can be used. The yellow (active) part of TachoSil facing toward you is brought into the defect so that the pressure pushes this part against the inner wall of the dura and a new TachoSil is brought from outside with the active side downwards. In some cases, a dura patch and a second layer with Spongostan can be performed. Once the dura defect is closed, a Valsalva maneuver is performed by increasing the ventilation pressure (PEEP 40 cm H<sub>2</sub>O for 30s). Postoperative maintenance is 48 hours with bed rest, where the first 24hrs are with a flat bed and the next 24hrs are with a 30° elevated torso. Antibiotics are maintained for three days. An example of this technique can be seen in Figure 1.

#### NT:

A distinction needs to be made between ID after anterior lumbar interbody fusion (ALIF), oblique lumbar interbody fusion (OLIF), and lateral lumbar interbody fusion (LLIF) approaches, because different treatments can be used according to the approach. ALIF allows for the possibility of visualization of the dural sac and placing a non-suturable dura patch with a fibrillar sealant (Figure 2). It is very difficult to perform a direct dural defect repair. ID during an oblique or lateral approach is caused by inadequate direction of the discectomy or during the cage placement. The visualization of a dural defect is not possible during an oblique or lateral approach and the treatment is performed by covering the cage with fibrillar surgical. The fibrillar surgical reabsorbs in 2 weeks without interference with fusion. I have not observed a CSF fistula during a lateral approach, only in oblique. The postoperative maintenance is bed rest for 72 hours (Figure 3). The placement of a lumbar catheter for 72 hours of CSF drainage is performed only if continuous CSF drainage is observed.

#### JL & MW:

A CSF leak is highly unusual during LLIF or ALIF. The reason is that the posterior longitudinal ligament shields the thecal sac during both approaches. An exception would be if attempting removal of a posterior central disc by an anterior approach. If a CSF leak is encountered in either approach, the first step is to tamponade the leak with a cottonoid in order to gain control of the situation. It is important to confirm that the leak is, in fact, CSF. The surgeon should attempt to visualize the defect, but this may be difficult or impossible. For the typical discectomy and interbody fusion, the exposure corridor is not adequate for suturing a defect. It is critical to reevaluate the surgical technique and fully understand the reasons why this event occurred, particularly if it was the result of a sequential set of errors that could potentially jeopardize the success of the surgery or patient safety. We do not recommend primary closure of the dural defect as it would be virtually impossible to obtain a watertight closure. The recommendation would be to place a collagen matrix dural substitute, such as DuraGen, over the defect followed by the

application of a thin layer of polyethylene glycol hydrogel dural sealant, like DuraSeal. The placement of the interbody graft may then proceed, which may also have a tamponing effect. The extent of the durotomy and the active leak following placement of the dural seal are essential information to define the benefit from postoperative lumbar CSF drainage. If so, this may be placed in operating theater following completion of the surgery. The patient will require strict bedrest for 24-48 hours with the head of the bed flat to decrease the hydrostatic pressure on the dural tear. In addition, anything that may increase intrabdominal pressure, such as constipation, must be aggressively avoided/treated. After 48 hours, the head of the patient's bed may be slowly elevated, and the patient mobilized with careful attention to the possibility of a positional headache. If the patient develops intractable positional headache, lumbar spine MRI without contrast should be obtained to assess any CSF collection and consideration should be given to proceeding with an epidural blood patch vs. the need for initiation of CSF diversion and a longer period of recumbency. Management is always on a case-by-case basis. In order to avoid the ID, it is recommended to not veer too far posteriorly from the surgical target during the lateral approach and to carefully remove posterior central disc herniation during the anterior procedure, particularly if adherent to the dura.

**SR:**

The incidence of ID and CSF leak in the lateral or anterior approach is rare due to the protective nature of posterior longitudinal ligament. Direct repair of ID is virtually impossible because of limited working area and poor visualization. I would recommend sealing of the leak using a layer of dural patch, collagen matrix dural substitute (e.g. DuraGen) over which a thin layer of fibrin sealant (e.g. Tisseel) can be applied to ensure complete sealing. If the leakage is near the foramen, it is important to use a small amount of Tisseel glue to avoid nerve compression. In cases where there is a high CSF flow, a posterior lumbar CSF catheter drainage is placed. There is no agreement in the literature about the importance and duration of bedrest. I allow the mobilization of the patient 24 hours after surgery if they do not complain of any headache on sitting and walking. Prevention of such a situation requires having good visualization, illumination, and developing a good tissue plane between the disc and the adjacent tissues.

**Scenario 2:** The surgeon was performing a MIS-TLIF approach through tube and the dura mater was torn at the nerve root exit during the cage placement with CSF leakage.

**YK:**

It is necessary to convert to open surgery to have enough room to repair the dura. Direct repair should be tried using micro set and magnification, followed by placement of fibrin glue and polyglycol acid sheet. The insertion of closed-suction drainage is not necessary if direct dura mater repair is performed, otherwise, drainage with low pressure is carried out. When used, the drain is removed the next day after surgery if the amount of CSF discharge is small. The occurrence of this complication can be minimized by practical training on a cadaver or simulation and close supervision by skilled surgeons before performing MIS surgery.

**BS & KW:**

The procedure is to avoid further CSF loss by using viscose pads. Proceed to further decompression until you see the whole dura defect to determine the possibility of stitching the dura. Usually it is almost impossible to suture the dura at the root exit. When it is possible to stitch the dura, be careful not to narrow the root. Patch with TachoSil and, if possible, perform the Sandwich technique. Evaluate the efficacy of the dura closure with a Valsalva maneuver. The postoperative care is bed rest for 48 hours in a flat position during the first 24h, and a 30° elevation of the torso for the following 24 hours. Antibiotic is maintained for three days.

**NT:**

There are three moments in which we increase the risk of dura mater injury during lumbar MIS TLIF: (1) during the drilling for laminectomy or facetectomy, (2) when using the angulated Kerrison in the foraminotomy or resection of the yellow ligament, and (3) during the retraction of the nerve root and the dura, especially in older adults. The tips to avoid tears of the dura mater during placement of the cage are to prepare enough room for cage placement by drilling the external and internal facet, avoiding blinding during the use of hammer, and wide discectomy using curettes, shavers, and cage test. Proceed with any direct decompression before the cage placement. In the case presented, it is necessary to consider the following variables: the location of the fistula, the shape of the defect, and the size of the defect. Regarding the location of the fistula, it is possible to repair the dura with monofilament 5-0 if the durotomy is posterior or lateral, but not in ventral dura defects. The shape of the suture can be linear or a round hole or irregular edges. The linear defect allows a direct suture, however in later dura defects, trying to suture increases the defect and it is better to cover it with a non-suturable dural patch fragment. It is essential to extend the laminectomy or foraminotomy to identify the dura edges and define the size of the dura defect. When the dura edges are not defined, it is preferable to cover with a non-suturable dural patch and fibrillar sealant. Sometimes it is necessary to convert the surgery to a Wiltze approach to reach those goals. Bed rest for 24 hours is indicated when it was possible to perform primary closure, reinforced with patch and fibrillar sealant. Bed rest for 72 hours is recommended if primary dura closure was not possible, and the ID is only managed with dural patch and fibrillar sealant. A flowchart of the management is presented in Figure 4.

**JL & MW:**

CSF leak during tubular MIS-TLIF is an unfortunate complication. It is important for the surgeon to remain calm and act in a systematic manner. Often the tear is secondary to inadequate retraction of the thecal sac at that depth, with the cage tearing the dura on initial insertion. This can also be due to inadequate facet joint removal, forcing the cage medially with impaction. The cage should be carefully removed if it has not been completely inserted. A cottonoid patty should be placed to control the leak, while the dura and nerve roots are carefully inspected for any obvious injuries. The intraoperative neurophysiologist should then be asked to evaluate for any changes. The bony exposure is widened as necessary, to try and see the edges of the dura defect.

The dura should be retracted again using a cottonoid and nerve root retractor, and the interbody graft inserted, taking extra care to not further damage the dura. Direct repair with stitching should be attempted when possible. A lateral or ventral dural tear is more challenging for direct repair. Appropriate hemostasis should be achieved followed by layering a small piece of collagen matrix dural substitute over the defect, such as DuraGen, followed by the application of a thin layer of polyethylene glycol hydrogel dural sealant. The tube is removed, and the procedure should proceed to completion. Postoperatively the patient should remain with the head of the bed flat and on strict bedrest for 24-48 hours to facilitate healing. In addition, anything that may increase intrabdominal pressure, such as constipation, must be aggressively avoided/treated. After this time, the head of the patient's bed may be slowly elevated, and the patient mobilized with careful attention paid to the development of a positional headache. Positional headache is relatively common as a result of CSF leak, however patients with intractable positional headache should have a lumbar spine MRI to rule out any large CSF collections, and evaluate the indication of epidural blood patch. The tubular approach to MIS-TLIF portends a good prognosis for CSF fistula formation as very little dead space is created by the procedure. CSF diversion is usually unnecessary. The optimal method by which to avoid this complication is to ensure adequate bony exposure from the beginning, which will allow appropriate mobilization and retraction of the thecal sac in order to ensure safe insertion of the interbody device.

#### AP:

Most dural lacerations in MIS TLIF happen during the cage insertion. In the case presented, the treatment is related to the size of dura laceration. If the dura tear is small, it is managed by sealing glue, such as Duraseal Exact Spine Sealant System, a polymer composed of polyethylene glycol ester solution and a trilycine amine solution. Other products used are Adherus or Tissucol. In a larger laceration with protrusion of roots through the hole, sometimes it is difficult to put back the roots intradurally because of high CSF pressure. In those cases, the roots are held in position with a dissector or hook while the pressure is reduced by CSF leak, so the roots can be easily put back into the sac. Then a dural patch of Tachosil is used to close the dural defect and sometimes fibril glue is also used above the patch. Direct dural closure must always be attempted, even for large dural openings. Metallic vascular clips can be used or dural stitches with 4/0 silk or 5/0 or 6/0 Vycril. Direct stitching is difficult in tubes smaller than 22, the usual size for MIS TLIF, especially if the tube is longer than 70- 80 mm. After the dura closure a dural sealant, such as Tissucol or Adherus, is inserted. If closure cannot be guaranteed by this procedure, then the surgeon must consider converting the surgery to open or increasing the length of the skin incision and muscular dissection to be able to close the dura safely. Patients are kept in bed for 24 hours. In our experience longer bedtimes are not beneficial and may increase the risk for other complications such as deep venous thrombosis. Patients with a dural tear are recommended to stay at hospital for 2-3 days to rule out any further complications, and to visit the surgeon within the next week. Usually it is not necessary to place a catheter for CSF drainage. The technical points to avoid dural tears in microsurgical tubular lumbar surgeries are: (1) separation of the yellow ligament from the underlying dura with a ball tipped bayonetted hook, (2) consider the

use of 90° Kerrison when performing contralateral laminectomy or working caudally or cranially in the midline, (3) move the Kerrison slightly to the sides before biting to identify movements of the dura that indicate the Kerrison is biting it, (4) use the matchstick drill, that has a lateral cutting edge to drill the lamina over the yellow ligament, providing protection to open the ligament and the dura when compared with a ball tip, (5) increase the protection of the dura and the exiting nerve root during the cage insertion by using two dural retractors. When MIS-TLIF and additional bilateral spinal canal decompression are needed, for example in a patient with spondylolisthesis with canal stenosis, the recommendation is to first perform the TLIF and later the bilateral laminectomy. CSF leak during laminectomy causes profuse epidural bleeding on the surgical field, increasing the risk of damaging the exiting nerve root because of inadequate visualization. Synovial cyst is the pathology with the highest incidence in intraoperative CSF leak. The main cause is the difficulty in identifying the dissection plane between cyst and dura, especially during ipsilateral approach. In synovial cyst cases, it is recommended to use the contralateral side for the approach to avoid the need for resection of the facets and better visualization of the interface cyst wall and dura. On the contrary, a CSF leak usually occurs in contralateral decompression and cranio-caudal laminectomy during tubular lumbar bilateral decompression.

#### SR:

MIS-TLIF is a very commonly performed procedure for a variety of indications and mastering a safe technique is vital to avoid this complication. ID can occur during decompression either when using burr or Kerrison, mainly in revision surgery due to fibrosis. If there is a wide opening ID with prolapse of nerve roots, it would be ideal to convert into a miniopen Wiltse approach and suture the rent after repositioning of the rootlets. Another situation in which ID can be observed is during the cage placement. This situation is caused by the limited room to medially retract the nerve root/dura, or insufficient removal of facets to allow sufficient lateral entry of the cage. It is always a good principle to insert the cage with the lateral margin of the dura retracted and still visualized during insertion. When this is not possible, I would remove more bone to allow a lateral entry. Although there is no scientific proof, I adopt a protocol to avoid the PEEP during ventilation and also use the bare minimum tidal volume, both of which are effective in reducing the intradural pressure and helpful in reducing dural damage during difficult decompressions. If there is a leak, it happens at the lateral border of the nerve root and usually an irregular rent. We have rarely encountered a clean linear rent that is amenable to suturing. When a rent around the nerve root happens, I usually place a dural seal or a few layers of Surgicel Fibrillar (Absorbable Hemostat by Ethicon) so that retraction of the dura can be done without further damage. With safe retraction, I would complete the surgery and then look into the appropriate method of dealing with the rent. Usually I use a layer of dural patch, like collagen matrix dural substitute (e.g. DuraGen) over which a thin layer of Tisseel is used to ensure complete sealing of the dural tear. It is important that the nerve root and the lateral border of the dura remains adequately decompressed when sealants are used.

**Scenario 3:** An expert endoscopic surgeon observed during a pure endoscopy technique a 1cm durotomy while the dural sac was retracted to expose the lumbar disc herniation.

**YK:**

Unfortunately, this situation sometimes occurs when the operation is done with the use of some force. Care must be taken throughout the operation. It is necessary to convert to open surgery to have enough room to repair the dura. It is difficult to address this type of dural tear under pure endoscopy.

**BS & KW:**

If the 1cm defect is a slit and especially if it is under the ligamentum flavum it can be patched, otherwise, if the defect is more a hole we would switch to a microscopic procedure. The technique under the microscope is the same as in the previous case: avoid further CSF loss with, for example, viscose pads; decompression until you see the whole dura defect; reponne fibers if needed; place an inside patch with Tachosil; stitch the dura whenever it is possible with Prolene 6/0; have a second layer of Tachosil from outside with the active side downwards or, alternatively, use a dura patch, for example tissue dura; test the sutures with the Valsalva maneuver by increasing the ventilation pressure (PEEP 40 cm H<sub>2</sub>O for 30s); muscle flap if necessary; and a multilayer closure. Postoperative care with 48 hours of bed rest, of which 24h flat and the next 24h 30° elevation of the torso and antibiotics for three days.

**JL & MW:**

Durotomy complicating percutaneous endoscopic discectomy is a rare occurrence. In pure endoscopic technique, no significant dead space is created by the procedure, limiting the extent to which an extradural CSF collection may form. For small uncomplicated durotomies we would not recommend aggressively attempting to repair the dura. The patient should be admitted for observation and maintained on bedrest with the head of the bed flat for a period of 24 hours. At that point the patient may be mobilized and as long as no significant positional headache is encountered, the patient may be discharged home. If the defect is of substantial size or if the patient does complain of significant positional headache then consideration should be given to 2 or 3 days of CSF diversion in the form of a lumbar drain. If a more significant durotomy is encountered with exposed nerve roots, closure followed by conversion to an open procedure for direct dural repair must be considered (Figure 5). Avoiding this complication in endoscopic surgery requires a clear understanding of endoscopic anatomy and potential safe and danger zones. The beveled tip of the endoscopic working channel may be used to both protect and retract the thecal sac and nerve roots, facilitating safe decompression.

**SR:**

The decision depends upon the location and type of dural defect. If a decision is made to repair, then we would convert the procedure into a microsurgical approach with a wider fenestration and proceeding on to a classical dural repair. The effectiveness of the repair can be checked by a



Valsalva maneuver. In effective repairs, there is no need for any further procedure or change of postoperative protocol. In cases where a repair is not possible, the alternative is to use a layer of absorbable dural patch collagen matrix dural substitute (e.g. DuraGen) and a thin layer of Tisseel.

**Scenario 4:** Patient returns to the office on postoperative day 7 of one level L3-L4 fusion with a severe headache that is worse in the standing position and relieved by recumbency. The surgical techniques used were lateral approach for cage placement and the paravertebral posterior approach for nerve decompression (laminotomy) and percutaneous pedicle screw. CSF leakage was observed at the paravertebral posterior incision.

YK:

CSF leak usually occurs in the posterior approach. I usually perform MRI and, specifically in this case, myelography is also indicated to check the area of the dural tear. The surgeon should act immediately to avoid a surgical site infection and meningitis. I would perform direct dura repair through open conversion. For a small dural tear or if an efficacious dural repair is not possible, a fibrin glue and polyglycol acid sheet is placed at the lesion. If the CFS leak is massive, a lumbar drainage system is added. A prophylactic antibiotic is indicated along with close postoperative care for the occurrence of fever, wound check, and blood test examination. The patient usually leaves the hospital on the 10<sup>th</sup> to 14<sup>th</sup> postoperative day.

BS & KW:

The investigation is performed by clinical examination, MRI, general blood tests for clinical evaluation and infection diagnosis, and examination of the liquid with  $\beta$ -Trace-Protein testing. The clinic and wound evaluation are mandatory in planning for revision surgery even without fluid detection by MRI in the operation area. If there are no clinical or radiologic signs of liquor leakage, conservative management is performed. On the contrary, if there is a suspicion of liquor leakage on MRI (Figure 6) where fluid is observed from the spine to the skin associated with leakage through an incision, an open surgery revision is planned. The tips and tricks for operation are: soft tissue reopening to identify the dura leakage; avoid further CSF loss using viscose pads; further decompression until you see the whole dura defect; repono fibers if needed; have an inside patch with Tachosil supplemented by a second layer from outside with the active side downwards; stitch the dura with Prolene 6/0 whenever possible. If necessary, a dura patch like Tissuedura or a muscle flap can be placed over the defect. Proof of closure is performed with a Valsalva maneuver by increasing the ventilation pressure (PEEP 40 cm H<sub>2</sub>O for 30s); and multilayer closure. CSF drainage is rarely necessary. The postoperative maintenance is done with 48h of bed rest, 24h with the bed in a flat position and the next 24h with a 30° torso. Antibiotic is used for three days.

NT:

If a lateral approach is performed, it is because an indirect decompression is the best option. Whenever a direct decompression is necessary, the best option would be a tubular

decompression, cage placement, and pedicle screw fixation, unless there is a marked alteration of the sagittal and/or coronal balance. In the present scenario of evident CSF fistula by the posterior wound, reoperation is indicated in order to close the dural defect with a primary suture and cover the dura with a patch and fibrillar sealant. It is unusual to have a CSF fistula in an operation through small paravertebral incisions. In that case, a high flow fistula is assumed, and bed rest combined with CSF diversion would not be an efficacious treatment. MRI is useful to determine if there is a contained fistula or soft tissue postoperative collected fluid, and helps plan the surgical revision according to the degree of injury to the muscles and bone adjacent to the dural sac. High-flow CSF fistulas occur in the early postoperative period and can be managed by tubular approach. In selected cases, the surgery can be reverted and extended to the Wiltse approach. It is essential to examine the cellularity and presence of bacteria in the fluid to determine the duration and type of antibiotic to be prescribed. Bed rest should be 72 hours. A flowchart of the management is presented in Figure 7.

JL & MW:

The risk of durotomy is higher in revision cases where there is distortion of normal anatomy and often dural adhesions and fibrosis. In some cases, incidental durotomy is unavoidable or may even go undetected as a pinhole that is not recognized at the time of surgery and further widens postoperatively. The patient in the present scenario has the classic symptoms of CSF leak with positional headache associated with drainage of clear fluid from the paravertebral incision. The diagnosis is clear cut. Evidence of active leakage from the wound necessitates urgent management. It is also important to rule out a concurrent infection. It is more likely that the durotomy occurred during posterior decompression than during lateral interbody placement. The patient should be admitted to the hospital and an MRI of the lumbar spine performed, preferentially with and without contrast. It is likely that a collection will be visible on the MRI and it may also be possible to ascertain the location of the durotomy. Surgical revision is indicated as soon as possible in an attempt to locate the leak. Intraoperative fluid cultures should be sent to the laboratory to customize the use of antibiotics. The dural defect should be repaired primarily whenever possible using 4-0 braided nylon suture. A Valsalva should then be obtained to ensure a water-tight closure. If there is evidence of continued leak, a muscle graft may be used as a dural patch. The surgical site should be washed with copious antibiotic-impregnated irrigation and a collagen matrix dural substitute, such as DuraGen, should be laid over the repaired durotomy, followed by application of a thin layer of polyethylene glycol hydrogel dural sealant. Preferentially, a subfascial drain is left and kept on self-suction. It is important to ensure closure of any dead space and obtain a water-tight fascial closure. The patient should remain in horizontal bedrest for 24 – 48 hours, followed by slow mobilization. The subfascial drain is removed 2-3 days postoperatively. Our preference is predicated on the belief that negative pressure applied within the subfascial space will expedite dural healing and assumes that our dural closure is strong enough to minimize additional removal of CSF from the subdural space. Proponents of a short period of self-suction, followed by placing the drain to gravity, argue that this method allows the subfascial CSF pressure to dictate the amount of drainage, and they have

also had good results.<sup>15</sup> Antibiotics are maintained until the drain is removed or maintained in the presence of concurrent infection. If the patient's symptoms are not improving, consideration must be given to re-exploration and/or a trial of CSF diversion with a lumbar drain. It is fortunate that with appropriate management, durotomies may be successfully managed and result in relief of the patient's symptoms.<sup>15</sup>

#### SR:

The most likely cause of dural tear is from the posterior procedure. Since the patient has an obvious CSF leak, there is no role for procrastination or conservative treatment. Since there is a delay of one week from surgery, the possibility of a concurrent infection through the leaking wound cannot be ruled out. Preoperative blood culture and adequate intraoperative CSF and tissue cultures must be obtained. MRI is usually very helpful to identify the site and size of the collection but frequently does not give a clue regarding the site and nature of the dural leak. The location of the dural defect should be identified and the decision for a direct repair or sealing technique is defined by the nature of the dural defect. Whenever possible, a direct repair should be attempted, and the effectiveness of the repair assessed by Valsalva maneuver. Even after direct repair we prefer to use a layer of absorbable dural patch. The wound is closed in layers by a watertight technique and the patient is mobilized within 24 hours. If direct repair is not possible, use a layer of absorbable dural patch (e.g. DuraGen) and thin layer of Tisseel, followed by a water-tight closure, a subfacial drain, and bedrest for 48-72 hrs. Antibiotic therapy will be for a minimum of three days, continued only if the cultures are positive. The use of continuous lumbar drain is uncommon.

#### Results

A summary of the expert management of CSF leakage for all four scenarios is presented in Table 1. The spinal biological products cited by the experts were: (1) fibrin sealant patch, such as Tachosil/Spongostan (Takeda corp Japan); (2) collagen matrix, like DuraGen® (Integra LifeSciences Corp., Plainsboro, NJ); (3) polyethylene glycol hydrogel, such as DuraSeal®, Integra LifeSciences Corp., Plainsboro, NJ); (4) fibrin sealant, like Tisseel (Baxter); (5) dural sealant – patch, such as Adherus ® (Stryker) or Tissucol ® (Baxter); and (6) polyethylene glycol hydrogel, such as Duraseal Exact Spine Sealant System® (Integra LifeSciences Holding Corp, NJ, USA).

In scenario 1, the majority of the surgeons recommended the use of dural patch, fibrin glue, and lumbar drainage considering the difficulty of direct suturing in the anterior or lateral approach. The time for bed rest ranged from 1 to 7 days. In scenario 2, most surgeons decided to extend the exposure to perform a direct dural suture followed by the use of a dural patch, fibrin glue, and multilayer closure. In scenario 3, the CSF leakage during endoscopic surgery usually would be treated with bed rest for 24 or 72 hours and, if necessary, lumbar drain. Scenario 4 would be treated by an open posterior approach, trying to find the lesion and promote a direct repair with multilayer closure. Dural patch and fibrin glue could also be used. Lumbar drain and bed rest for 1-3 days.

## Discussion

Considering the potential complications of ID after spinal surgery and the additional cost to the health system, proper identification and management should be established.<sup>16</sup> Papavero et al<sup>17</sup> described a ten step approach (10ST) to an identified CSF leakage. In a retrospective study, 46 patients were treated with the 10ST and 100% success was observed. Positioning the patient so that the defect is placed in a higher point than the ventricles helps to decrease the leakage. A microscope and proper instruments must always be available. The first step is to remove bone until you can see the whole dural defect. Secondly, the surgeon should do an intradural look to remove hematoma or possible bone fragments. The third step is to reposition extruded fibers with the help of cottonoids and low power suction. The fourth step is to do an inside patch if necessary, especially in defects larger than 5mm. The fifth step is dural closure. This is a crucial and well-described step in the literature<sup>3,18,19</sup> and should be done whenever possible. In this description prolene 5/0 to 7/0 were used but silk and nylon can also be tried. After suturing an outside patch is placed (6<sup>th</sup> step). To rule out CSF leak, a Valsalva maneuver is done raising the pressure up to 40 cm H<sub>2</sub>O and sustained for 30 s. If all previous steps fail, a muscle flap is placed into the dead space (7<sup>th</sup> step). Multiple layer closure is always performed (8<sup>th</sup> step). If the lesion is severe, lumbar CSF drainage can be done for a period of 3-5 days (9<sup>th</sup> step). In the majority of these cases, bed rest was limited to 24 hours (10<sup>th</sup> step).

Durand et al,<sup>9</sup> in an observational cohort study, described an overall incidence of late presenting dural tear (LPDT) of 2/1000 patients. Lumbar surgery, decompressive surgery alone, operative duration of more than 250 minutes, and associated cervical and lumbar surgery were all identified risk factors for LPDT. Direct independent association of LPDT with surgical site infection, sepsis, pneumonia, wound dehiscence, thromboembolism, and acute kidney injury was also observed.

Galarza et al<sup>23</sup> proposed a classification of intraoperative lumbar dural tear less than 1 cm in length and proposed a correlated treatment. Type I, or mild dural tear, consists of disruption of the dura with clean borders and minimal or no breach of the arachnoid associated with the exit of a few drops of CSF. Type II, or moderate dural tear, consists of disruption of the dura with clean borders, evident breach of the arachnoid, and multiple drops or a single line of CSF. Type III, or severe dural tear, consists of disruption of the dura with more than one border, gross breach of the arachnoid sometimes with protrusion of the rootlets or nerve roots, and persistence of several lines of CSF. The proposed treatment for all types is the application of tissue-glue coated collagen sponge or fibrin glue, in addition to direct dural suturing with prolene 5/0 in type III dural tears.

## Tips and tricks

- Dural closure. Dural closure is crucial and very effective, and should be done whenever possible.<sup>3,18,19</sup>
- Lumbar drainage. Brodano et al<sup>20</sup> proposed the placement of lumbar drainage for ten days with successful management of identified intraoperative CSFL. Tosun et al<sup>21</sup> reported the management of 12 patients with persistent CSF leakage following thoraco-lumbar surgery. Five patients were treated with lumbar drainage and 7 with over-sewing of the wound showing that pseudomeningocele can be addressed by lumbar drainage and, in patients without neurological deficit, over-sewing of the wound can be an option.
- Biologic therapy with fibrin glue, collagen, and blood patches. Thrombin and autologous blood seems to be effective to treat ID.<sup>22</sup> Primary dural closure combined with thrombin and autologous blood resulted in successful repair after lumbar spine surgery with less leakage and shorter hospital stay.<sup>22</sup>
- Bed rest. Bed rest is considered a treatment for ID.<sup>24,25</sup> Prolongation of bed rest for more than 24 hours does not appear to improve the outcomes and may be associated with complications such as thrombosis or pneumonia.<sup>24,25</sup> In a canine model, the cicatrization and healing of dural defects starts on the 6<sup>th</sup> day with fibroblastic bridging and ends on day ten.<sup>26</sup> The clinical translation of this study promotes some changes in practice, for example, maintaining lumbar drainage for ten days for the successful management of ID.<sup>20</sup>
- Dural leakage in anterior/lateral approach. There is no standard treatment for dural tear during an anterior approach and the majority of the spine surgeons would treat with a sealant alone.<sup>27</sup> The primary dural closure is very challenging. Rodgers et al<sup>28</sup> reported no dural tear in an analysis of 600 lateral approach cases. Another clinical study done by Baaj et al<sup>29</sup> identified a 2.5% incidence of dural tear in eighty patients who underwent a corpectomy through a mini open lateral approach, all cases successfully managed with dural sealants. In a multivariate analysis of risk factors for ID, Du et al<sup>30</sup> reported that old age, revision surgery, and laminectomies were all independent factors for ID during spine surgeries and that fusion foraminectomies and, markedly, the lateral approach to the lumbar and thoracolumbar spine were protective factors for ID in spine surgery.
- Dural leakage in open/MIS surgery. Ghobrial et al,<sup>1</sup> in a review of the literature, found a similar incidence of ID in open and MIS surgery. Wong et al<sup>4</sup> reported a significantly higher incidence of 9% ID in open procedures compared to 4.5% in MIS surgery, but one major confounder in the study was the higher percentage of revision surgery in the open procedure group (21.7 vs 16.0%). Whenever direct repair is not possible during MIS surgery it should be converted to open surgery.
- Dural leakage in full endoscopic approach. The ID in endoscopic procedures is as high as 8.6% without a consensus having been reached on management strategies.<sup>8</sup> Dural suturing by endoscopy can be very challenging and an effective treatment can be achieved using autologous muscle graft associated with fibrin sealant patch.<sup>6</sup> Positive pressure and almost no dead space are protective particularities of endoscopic surgery in IDs.

## Conclusion

Lumbar incidental durotomy can be treated in different ways depending on the spine surgeon's expertise and training, surgical technique, and the location and size of the dural defect. It is not possible to perform a direct repair of a dural defect using an anterior or lateral lumbar spine approach. When a dural defect occurs during the lateral or anterior lumbar approach, it is usually treated by dural patch and fibrin sealant. Lumbar drainage can be used for an incidental durotomy during a lateral or anterior approach, or for a larger dural defect or continuous CSF leakage. Bed rest is usually indicated for one to three days.

## References

1. Ghobrial GM, Theofanis T, Darden BV, Arnold P, Fehlings MG, Harrop JS. Unintended durotomy in lumbar degenerative spinal surgery: a 10-year systematic review of the literature. *Neurosurg Focus*. 39(4):E8, 2015.
2. Tafazal SI, Sell PJ. Incidental durotomy in lumbar spine surgery: incidence and management. *Eur Spine J*. 14(3):287-90, 2005.
3. Guerin P, El Fegoun AB, Obeid I, Gille O, Lelong L, Luc S, Bourghli A, Cursolle JC, Pointillart V, Vital JM. Incidental durotomy during spine surgery: incidence, management and complications. A retrospective review. *Injury*. 43(4):397-401, 2012.
4. Wong AP, Shih P, Smith TR, Slimack NP, Dahdaleh NS, Aoun SG, El Ahmadi TY, Smith ZA, Scheer JK, Koski TR, Liu JC, Fessler RG. Comparison of symptomatic cerebral spinal fluid leak between patients undergoing minimally invasive versus open lumbar foraminotomy, discectomy, or laminectomy. *World Neurosurg*. 81(3-4):634-40, 2014.
5. Rodriguez-Olaverrri JC, Zimick NC, Merola A, Vicente J, Rodriguez J, Tabuenca A, Loste A, Suñen E, Burgos J, Hevia E, Piza-Vallespir G. Comparing the clinical and radiological outcomes of pedicular transvertebral screw fixation of the lumbosacral spine in spondylolisthesis versus unilateral transforaminal lumbar interbody fusion (TLIF) with posterior fixation using anterior cages. *Spine (Phila Pa 1976)*. 33(18):1977-81, 2008.
6. Oertel JM, Burkhardt BW. Full endoscopic treatment of dural tears in lumbar spine surgery. *Eur Spine J*. 26(10):2496-503, 2017.
7. Sofianos DA, Briseno MR, Abrams J, Patel AA. Complications of the lateral transpoas approach for lumbar interbody arthrodesis: a case series and literature review. *Clin Orthop Relat Res*. 470(6):1621-32, 2012.
8. Muller SJ, Burkhardt BW, Oertel JM. Management of Dural Tears in Endoscopic Lumbar Spinal Surgery: A Review of the Literature. *World Neurosurg*. 119:494-9, 2018.
9. Durand WM, DePasse JM, Kuris EO, Yang J, Daniels AH. Late-presenting dural tear: incidence, risk factors, and associated complications. *Spine J*. 18(11):2043-50, 2018.
10. Weng YJ, Cheng CC, Li YY, Huang TJ, Hsu RW. Management of giant pseudomeningoceles after spinal surgery. *BMC Musculoskelet Disord*. 11:53, 2010.
11. Zhang LM, Ren L, Zhao ZQ, Zhao YR, Zheng YF, Zhou JL. Surgical treatment for bacterial meningitis after spinal surgery: A case report. *Medicine (Baltimore)*. 96(11):e6099, 2017.
12. Puvanesarajah V, Hassanzadeh H. The True Cost of a Dural Tear: Medical and Economic Ramifications of Incidental Durotomy During Lumbar Discectomy in Elderly Medicare Beneficiaries. *Spine (Phila Pa 1976)*. 42(10):770-6, 2017.

13. Gautschi OP, Stienen MN, Smoll NR, Corniola MV, Tessitore E, Schaller K. Incidental durotomy in lumbar spine surgery--a three-nation survey to evaluate its management. *Acta Neurochir (Wien)*. 156(9):1813-20, 2014.
14. Clajus C, Stockhammer F, Rohde V. The intra- and postoperative management of accidental durotomy in lumbar spine surgery: results of a German survey. *Acta Neurochir (Wien)*. 157(3):525-30, 2015.
15. Khan MH, Rihn J, Steele G, Davis R, Donaldson WF, 3rd, Kang JD, Lee JY. Postoperative management protocol for incidental dural tears during degenerative lumbar spine surgery: a review of 3,183 consecutive degenerative lumbar cases. *Spine*. 31(22):2609-13, 2006.
16. Menon SK, Onyia CU. A short review on a complication of lumbar spine surgery: CSF leak. *Clin Neurol Neurosurg*. 139:248-51, 2015.
17. Papavero L, Engler N, Kothe R. Incidental durotomy in spine surgery: first aid in ten steps. *Eur Spine J*. 24(9):2077-84, 2015.
18. Eismont FJ, Wiesel SW, Rothman RH. Treatment of dural tears associated with spinal surgery. *J Bone Joint Surg Am*. 63(7):1132-6, 1981.
19. Dafford EE, Anderson PA. Comparison of dural repair techniques. *Spine J*. 15(5):1099-105, 2015.
20. Barbanti Brodano G, Serchi E, Babbi L, Terzi S, Corghi A, Gasbarrini A, Bandiera S, Griffoni C, Colangeli S, Ghermandi R, Boriani S. Is lumbar drainage of postoperative cerebrospinal fluid fistula after spine surgery effective? *J Neurosurg Sci*. 58(1):23-7, 2014.
21. Tosun B, Ilbay K, Kim MS, Selek O. Management of Persistent Cerebrospinal Fluid Leakage Following Thoraco-lumbar Surgery. *Asian Spine J*. 6(3):157-62, 2012.
22. Moussa WM, Aboul-Enein HA. Combined thrombin and autologous blood for repair of lumbar durotomy. *Neurosurg Rev*. 39(4):591-7, 2016.
23. Galarza M, Gazzeri R, Alfaro R, de la Rosa P, Arraez C, Piqueras C. Evaluation and management of small dural tears in primary lumbar spinal decompression and discectomy surgery. *J Clin Neurosci*. 50:177-82, 2018.
24. Low JC, von Niederhausern B, Rutherford SA, King AT. Pilot study of perioperative accidental durotomy: does the period of postoperative bed rest reduce the incidence of complication? *Br J Neurosurg*. 27(6):800-2, 2013.
25. Robson CH, Paranathala MP, Dobson G, Ly F, Brown DP, O'Reilly G. Early mobilisation does not increase the complication rate from unintended lumbar durotomy. *Br J Neurosurg*. 1-3, 2018.
26. Cain JE, Jr., Lauerman WC, Rosenthal HG, Broom MJ, Jacobs RR. The histomorphologic sequence of dural repair. Observations in the canine model. *Spine (Phila Pa 1976)*. 16(8 Suppl):S319-23, 1991.
27. Oitment C, Aref M, Almenawar S, Reddy K. Spinal Dural Repair: A Canadian Questionnaire. *Global Spine J*. 8(4):359-64, 2018.
28. Rodgers WB, Gerber EJ, Patterson J. Intraoperative and Early Postoperative Complications in Extreme Lateral Interbody Fusion: An Analysis of 600 Cases. *Spine (Phila Pa 1976)*. 36(1):26-32, 2011.
29. Baaj AA, Dakwar E, Le TV, Smith DA, Ramos E, Smith WD, Uribe JS. Complications of the mini-open anterolateral approach to the thoracolumbar spine. *Journal of Clinical Neuroscience*. 19(9):1265-7, 2012.
30. Du JY, Aichmair A, Kueper J, Lam C, Nguyen JT, Cammisa FP, Lebl DR. Incidental Durotomy During Spinal Surgery: A Multivariate Analysis for Risk Factors. *Spine*. 39(22):E1339-E45, 2014.

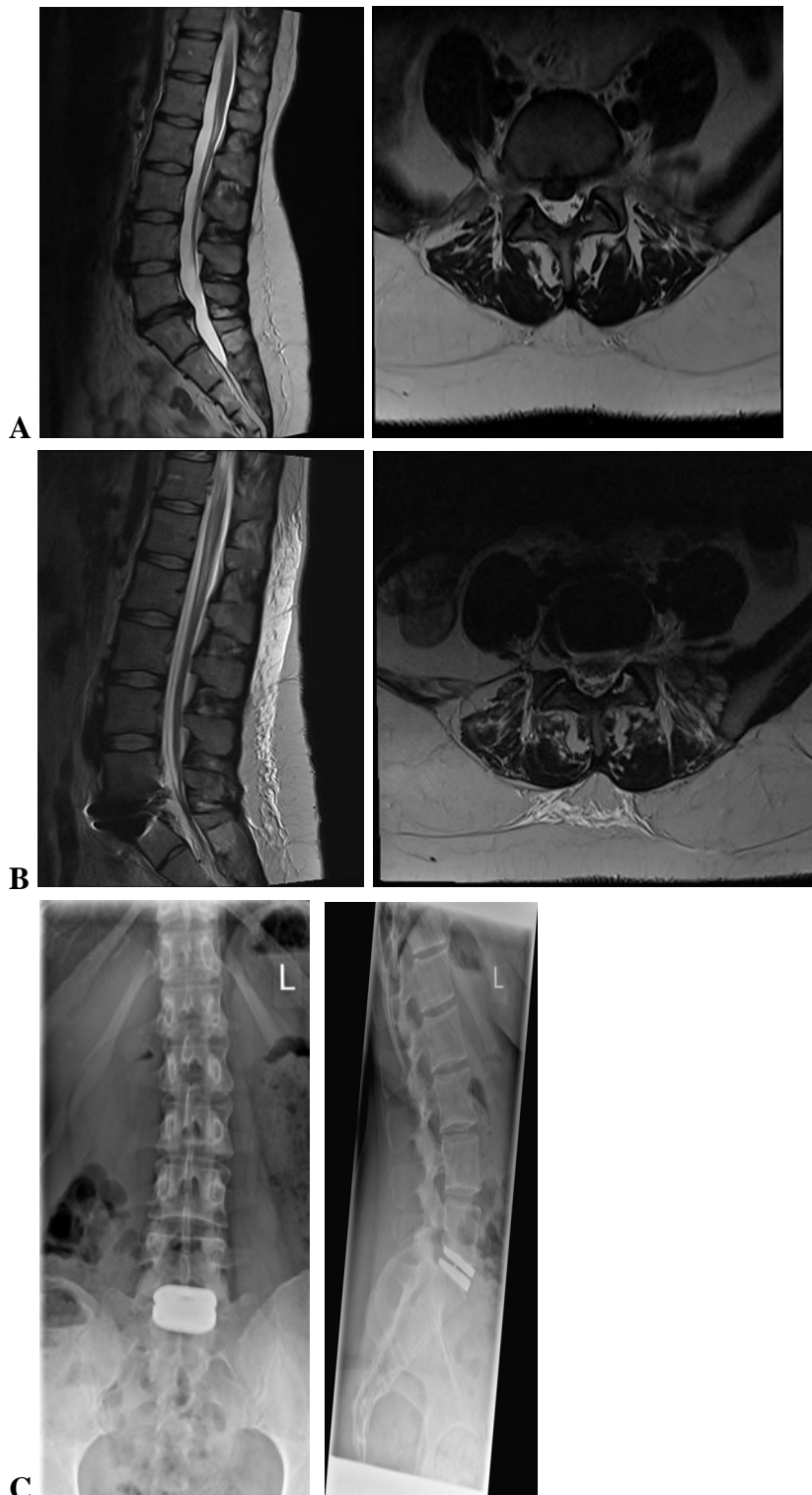
27. Rodgers WB, Gerber EJ, Patterson J. Intraoperative and Early Postoperative Complications in Extreme Lateral Interbody Fusion: An Analysis of 600 Cases. *Spine*. 36(1):26-32, 2011.
28. Baaj AA, Dakwar E, Le TV, Smith DA, Ramos E, Smith WD, Uribe JS. Complications of the mini-open anterolateral approach to the thoracolumbar spine. *Journal of Clinical Neuroscience*. 19(9):1265-7, 2012.
29. Du JY, Aichmair A, Kueper J, Lam C, Nguyen JT, Cammisa FP, Lebl DR. Incidental Durotomy During Spinal Surgery: A Multivariate Analysis for Risk Factors. *Spine*. 39(22):E1339-E45, 2014.



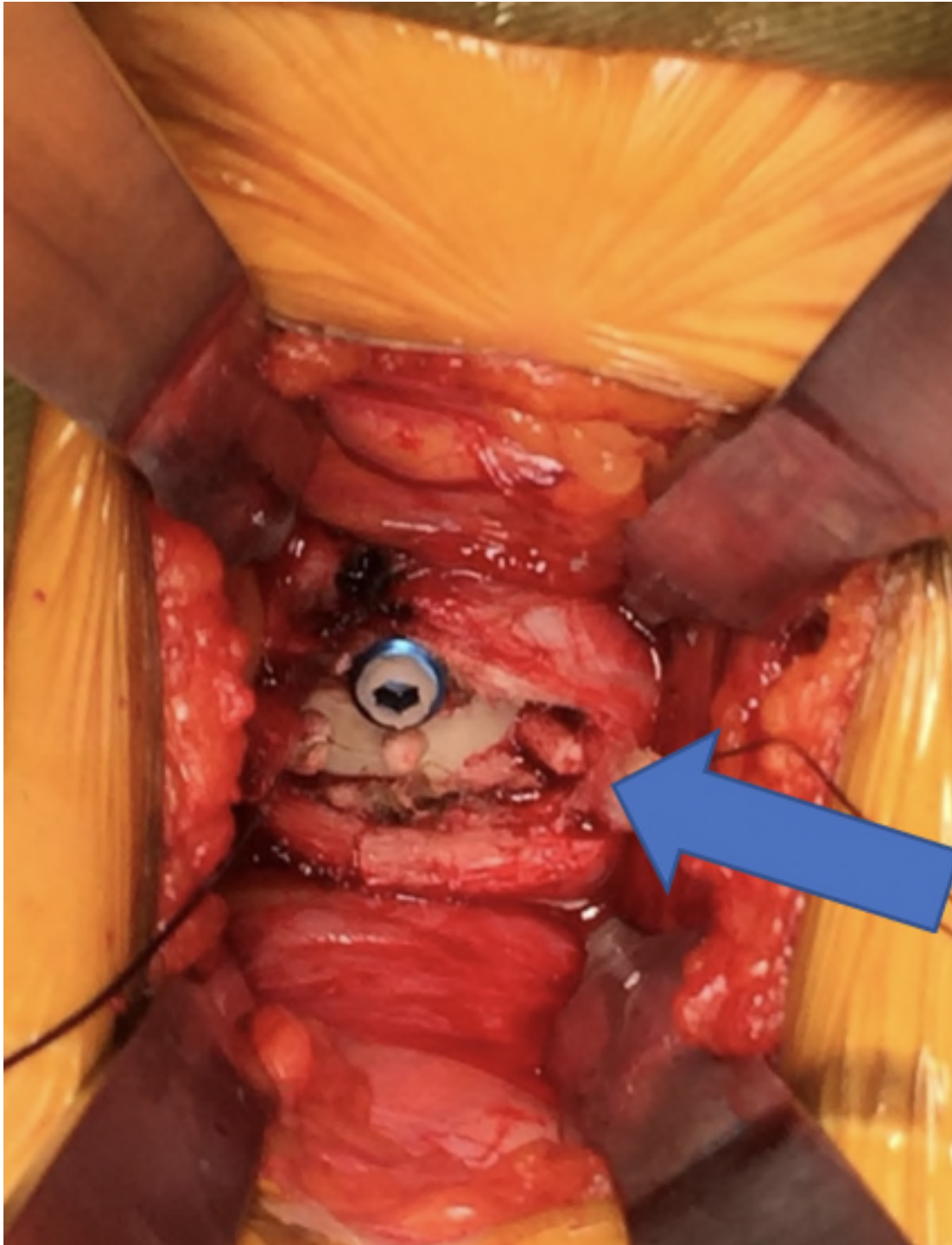
**Table 1: A summary of the expert management of CSF leakage presented in the different scenarios**

	Direct repair	Dural patch	Fibrin sealant	Lumbar drainage	Anti-biotics	Bed rest	Open exposure	How to prevent incidental durotomy
<b>Scenario 1</b>	No	Yes	Yes	Yes	No	1-7 days	No	Appropriate instruments with depth marks, careful removal of central herniation
<b>Scenario 2</b>	Yes	Yes	Yes	No	No	1-3 days	Yes	Appropriate training in cadaver or simulation, careful drilling and foraminotomy, wide space for placing the cage, and direct look during hammering.
<b>Scenario 3</b>	Yes	Yes	Yes	No	No	1-2 days	If nerve exposure or defect greater than 1 cm	Understanding of endoscopic anatomy, and potential safe and dangerous zones
<b>Scenario 4</b>	Yes	Yes	Yes	If massive CSF leak	According to fluid or blood culture	1-3 days	Yes	No role for procrastination or conservative treatment

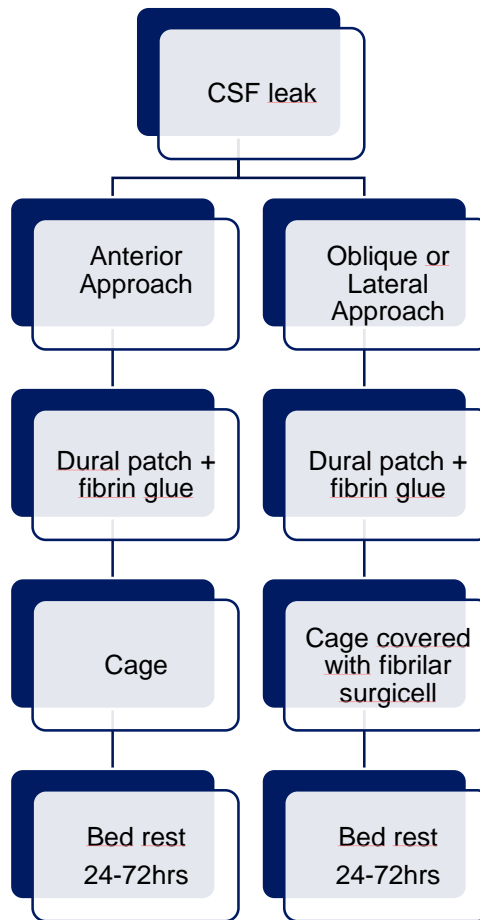
**Table 1.** A summary of the expert management of CSF leakage presented in the different scenarios.



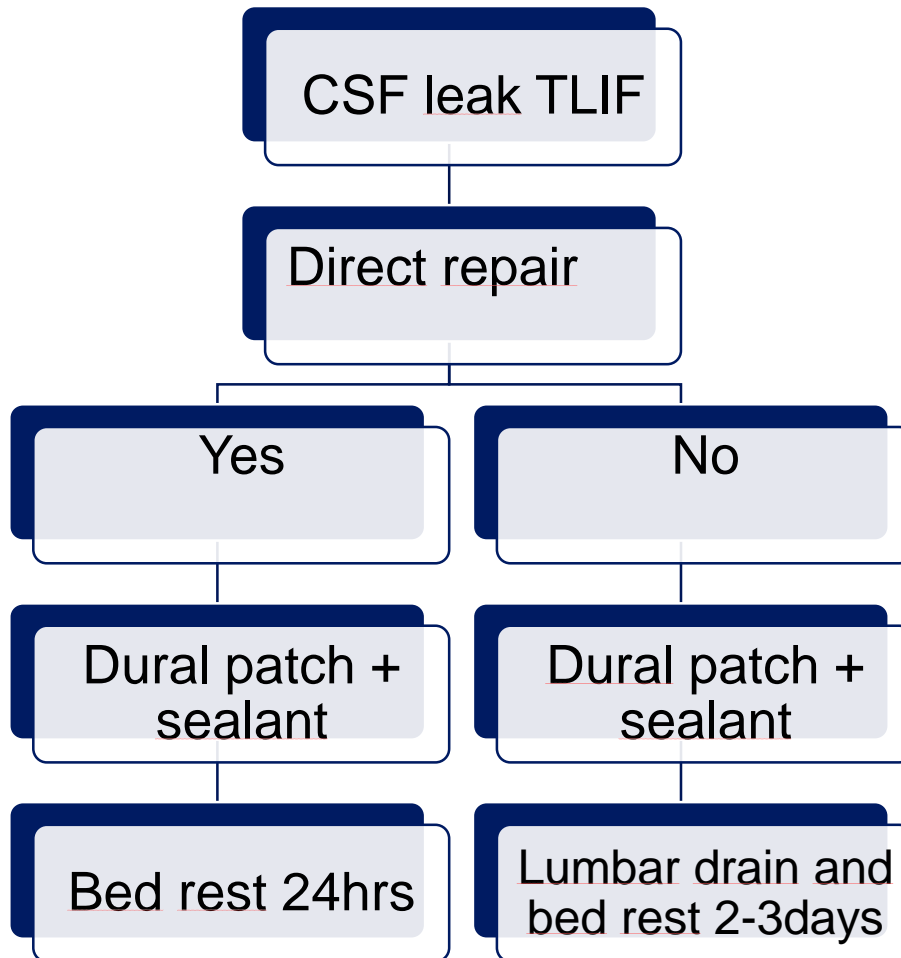
**Figure 1.** Patient with low-back pain caused by L5-S1 intervertebral disc degeneration and posterior central disc herniation. (A) Intraoperative incidental durotomy treated by fibrin sealant patch and bed rest for 48 hours. (B) Postoperative MRI images without cerebrospinal fluid collection and (C) one-year X-ray with good prosthesis position.



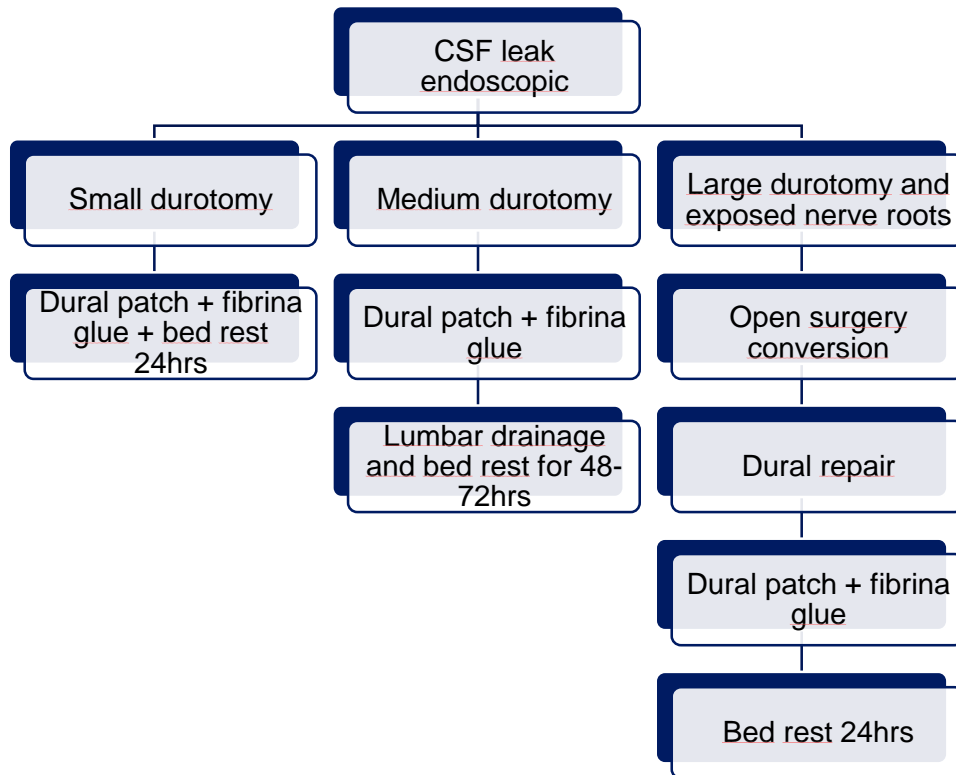
**Figure 2.** Intraoperative cerebrospinal leakage during an oblique lumbar approach treated by dura patch with a fibrillar sealant.



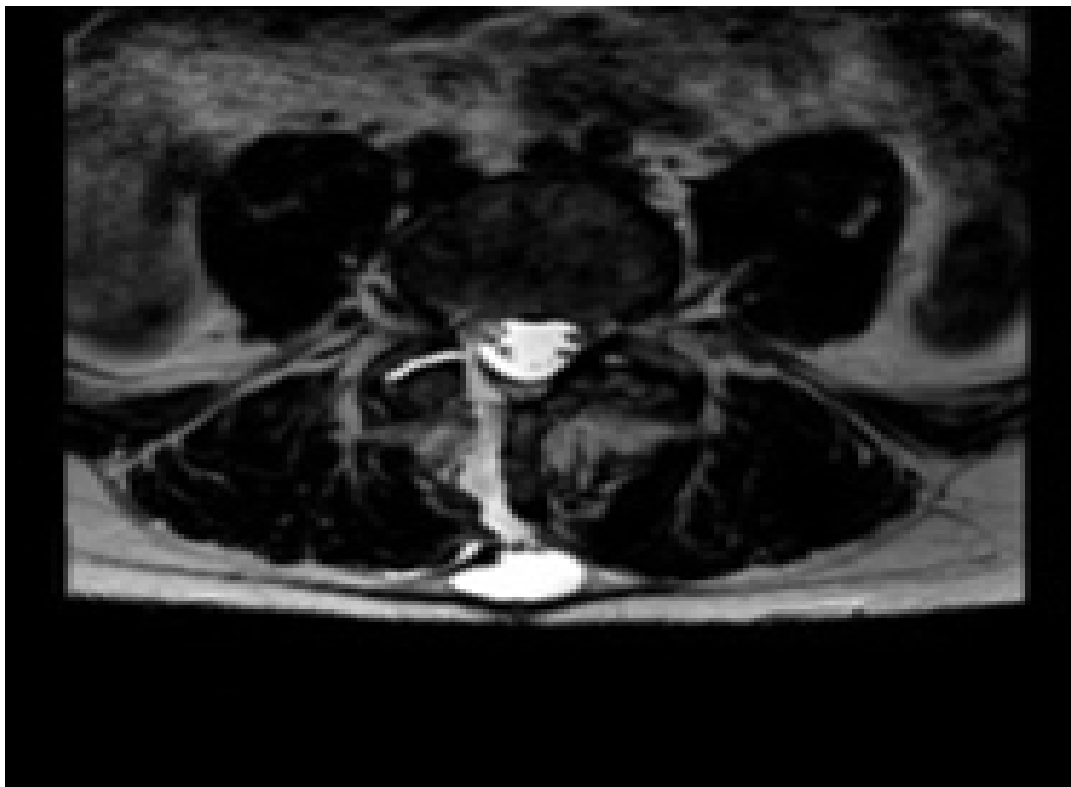
**Figure 3.** A flowchart of cerebrospinal fluid leakage after anterior and lateral approach.



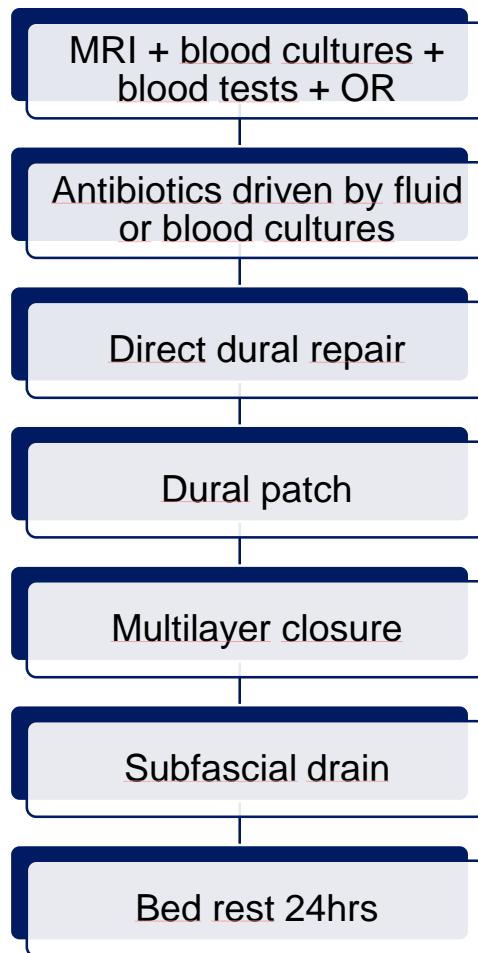
**Figure 4.** A flowchart of cerebrospinal fluid leakage after minimally invasive transforaminal lumbar interbody fusion.



**Figure 5.** A flowchart of cerebrospinal fluid leakage through endoscopic surgery in the lumbar spine.



**Figure 6.** Cerebrospinal fluid leakage after posterior approach at MRI where fluid is observed from the spine to the skin associated with leakage through an incision.



**Figure 7.** A flowchart of cerebrospinal fluid leakage through an incision after posterior approach to the lumbar spine.