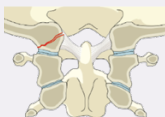
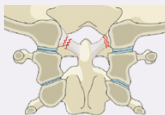
I. Occipital Condyle and Craniocervical junction

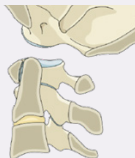Type A Isolated bony injury (condyle)



Type B Non-displaced ligamentous injury (craniocervical)

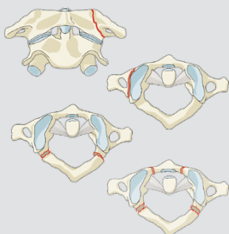


Type C Any injury with displacement on spinal imaging

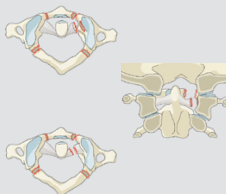


II. C1 Ring and C1-2 Joint

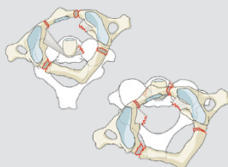
Type A Isolated bony only (arch)



Type B Ligamentous injury (transverse atlantal ligament)

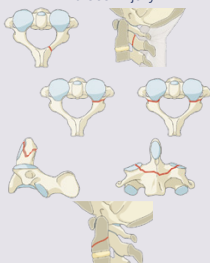


Type C Atlantoaxial instability / Translation in any plane

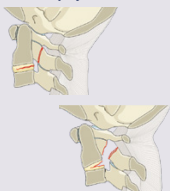


III. C2 and C2-3 Joint

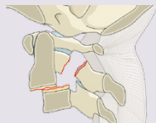
Type A Bony injury only without ligamentous, tension band, discal injury



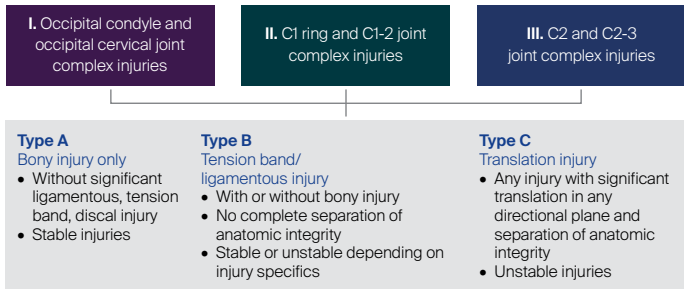
Type B Tension band / Ligamentous injury with or without bony injury



Type C Any injury that leads to vertebral body translation in any directional plane



Upper Cervical Spine Fractures Overview



Neurology

Type	Neurological
N0	Neurology intact
N1	Transient neurologic deficit
N2	Radicular symptoms
N3	Incomplete spinal cord injury or any degree of cauda equina injury
N4	Complete spinal cord injury
NX	Cannot be examined
+	Continued spinal cord compression

Modifiers

Type	Description
M1	Injuries at High Risk of Non-Union with Nonoperative Tx
M2	Injury with significant potential for instability
M3	Patient Specific Factors Affecting Tx
M4	Vascular Injury or Abnormality Affecting Tx

Classification Nomenclature

Atlanto-occipital dissociation with a complete spinal cord injury.

